



MAASSTAD ZIEKENHUIS




Hemorrhoids:

Medical / Instrumental treatment

BG Symposium, 21-01-2014


Pieter Dewint

MD, PhD

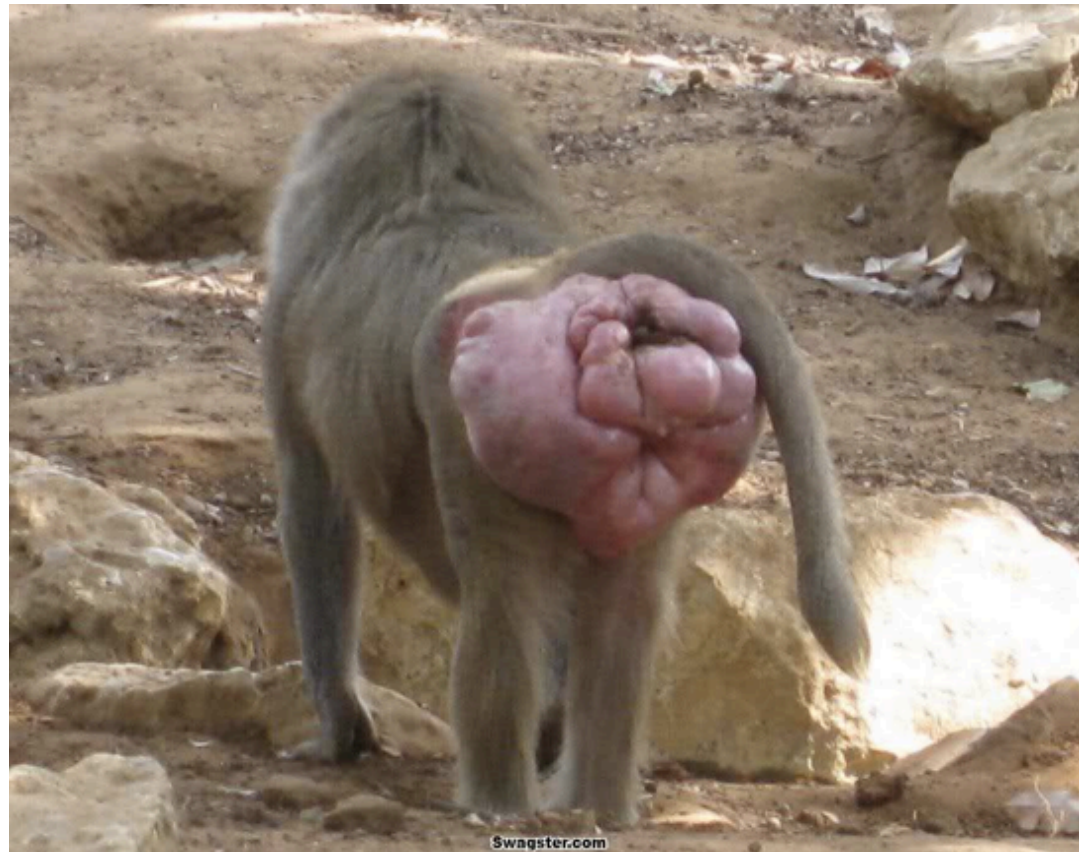


Disclosure belangen spreker

(potentiële) belangenverstremgeling	Geen
Voor bijeenkomst mogelijk relevante relaties met bedrijven	Bedrijfsnamen
<ul style="list-style-type: none">• Sponsoring of onderzoeksgeld• Honorarium of andere (financiële) vergoeding• Aandeelhouder• Andere relatie, namelijk ...	<ul style="list-style-type: none">••••

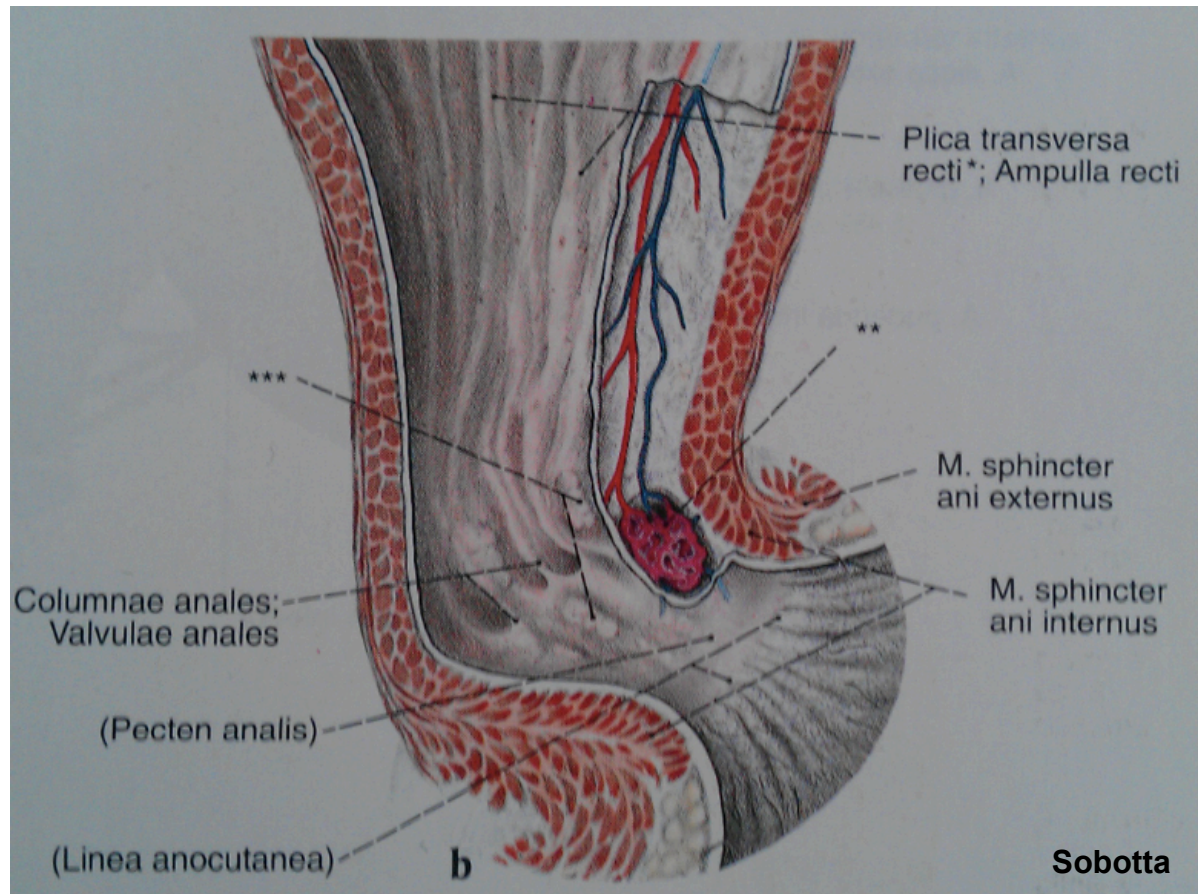



Hemorrhoids and The Internet



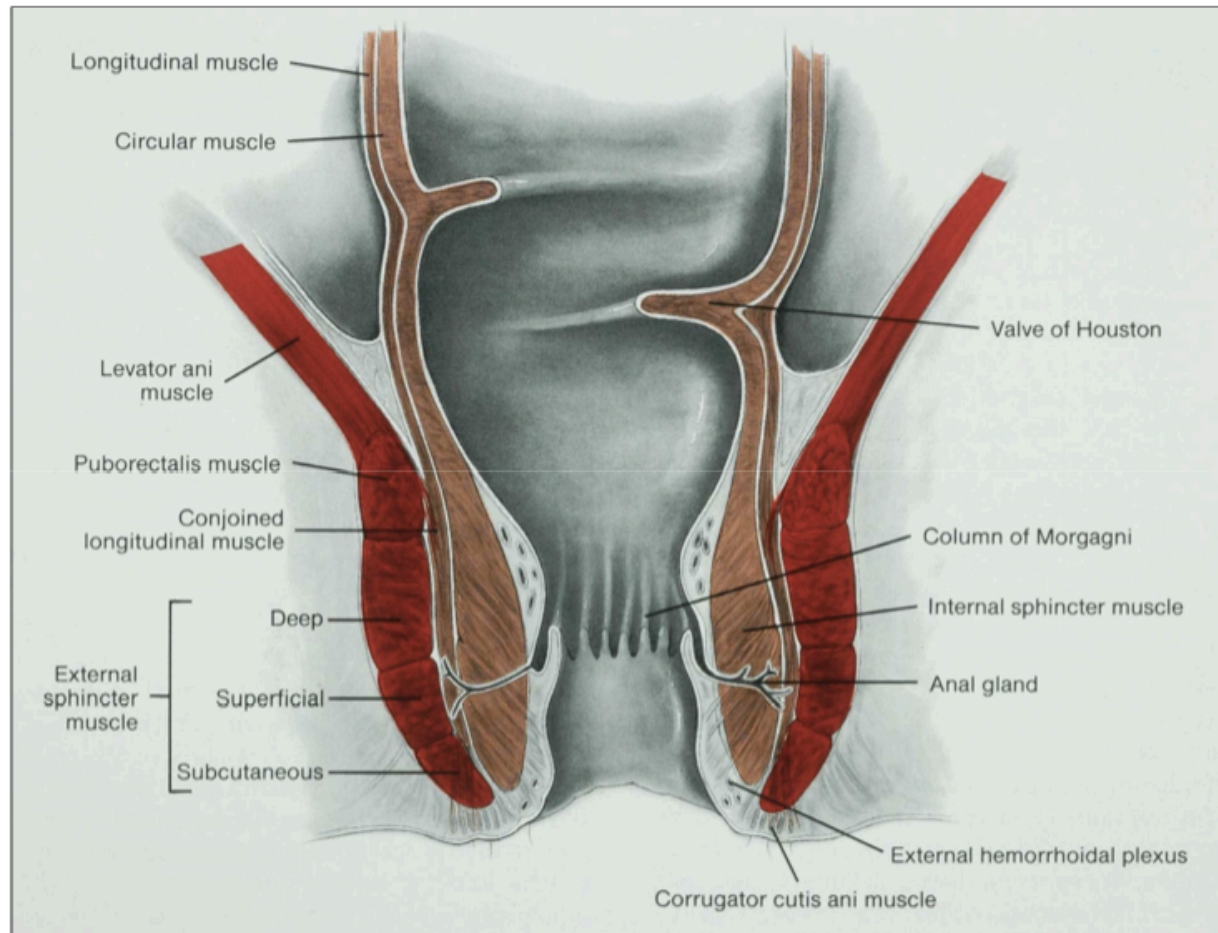



Internal / External Hemorrhoids



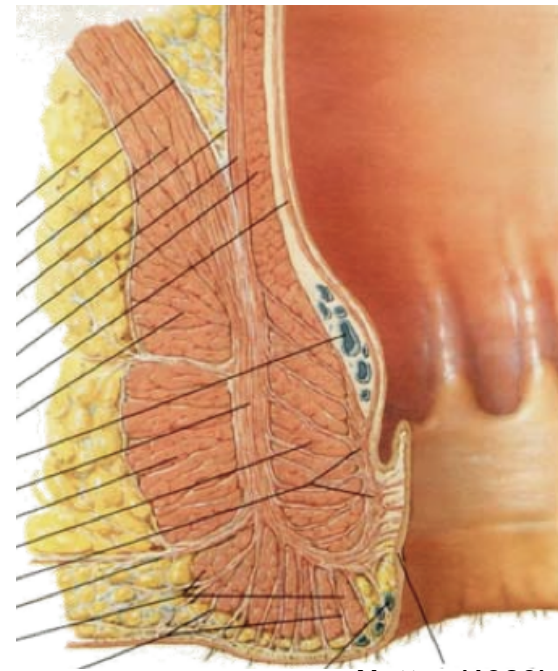
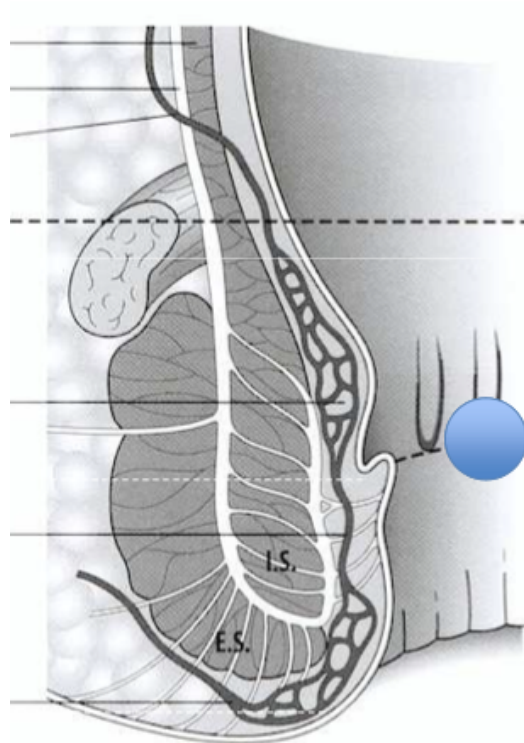


Internal / External Hemorrhoids






Internal / External Hemorrhoids

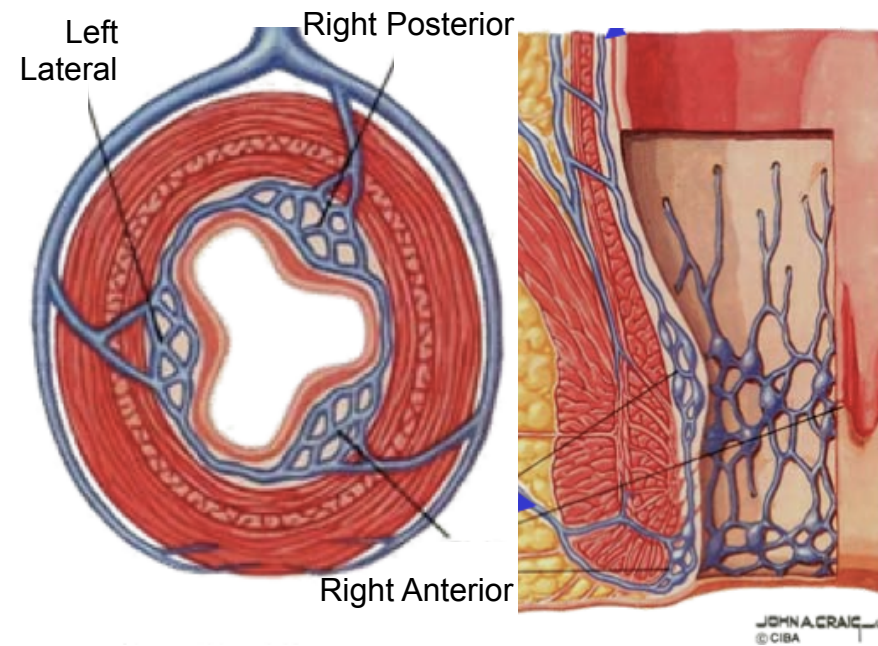



Netter (1989)



Anatomy

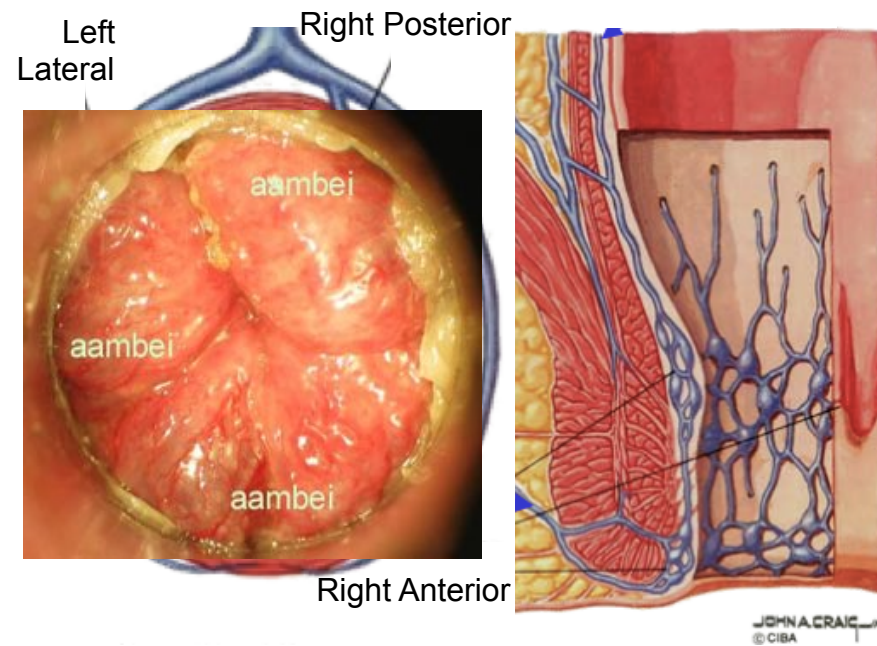
Three Cushions






Anatomy

Three Cushions






God, Thanks for the hemorrhoids!

Some historical aspects



De slag van Waterloo, Jan Willem Pieneman, 1824




God Thanks, I've got Hemorrhoids

Physiological aspects


Maintaining continence

Rest pressure: hemorrhoids: 15-20 %



God Damn, I've got Hemorrhoids

- Internal hemorrhoids
 - Prolapse
 - Bleeding
 - Thrombosis
- External hemorrhoids
 - Thrombosis
 - Mariske / skintag




Internal Hemorrhoids: Prolapse

Grade I: congested hemorrhoids, no externalization

Grade II: passing beyond linea dentata
with spontaneous reduction

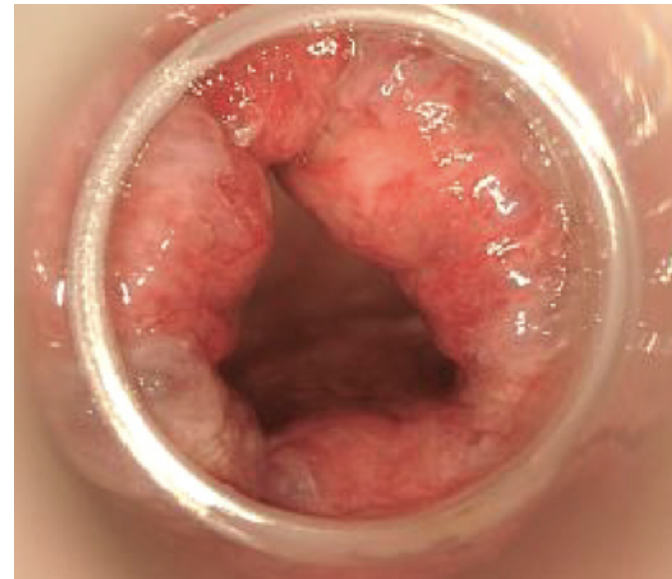
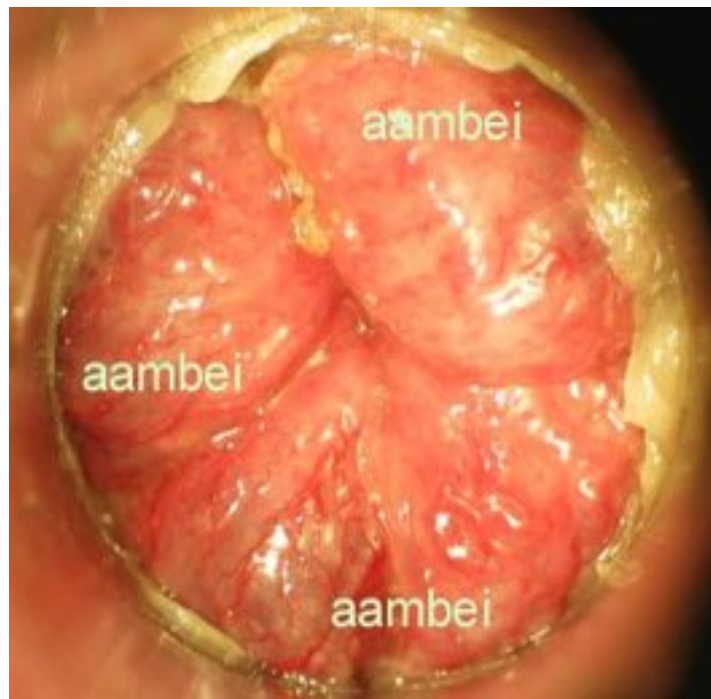
Grade III: manual reduction of hemorrhoids


Grade IV: reduction of hemorrhoids not possible



Internal Hemorrhoids: Prolapse

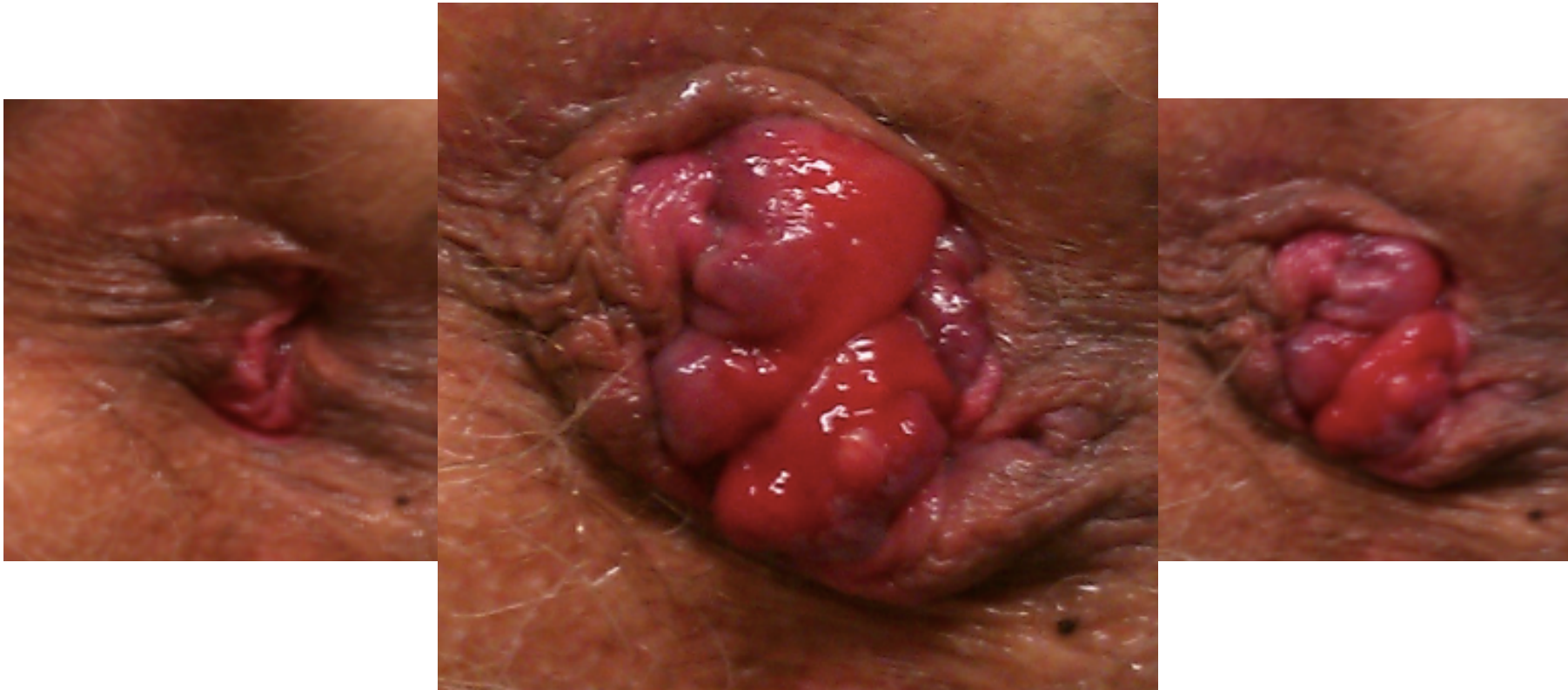Grade I : congested hemorrhoids, no externalization






Internal Hemorrhoids: Prolapse

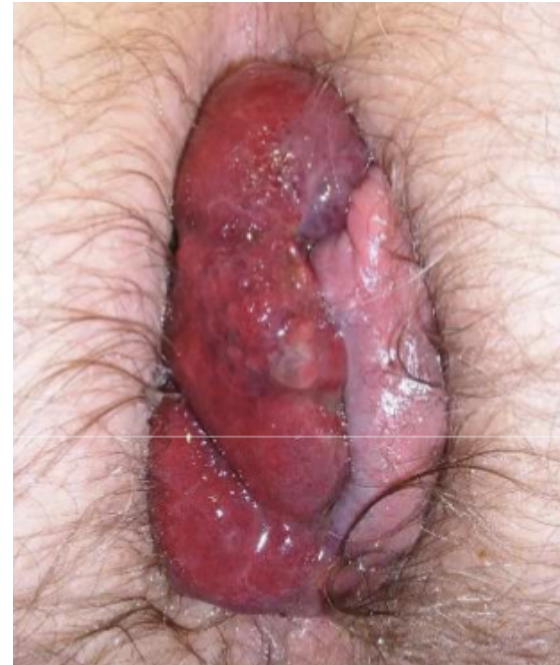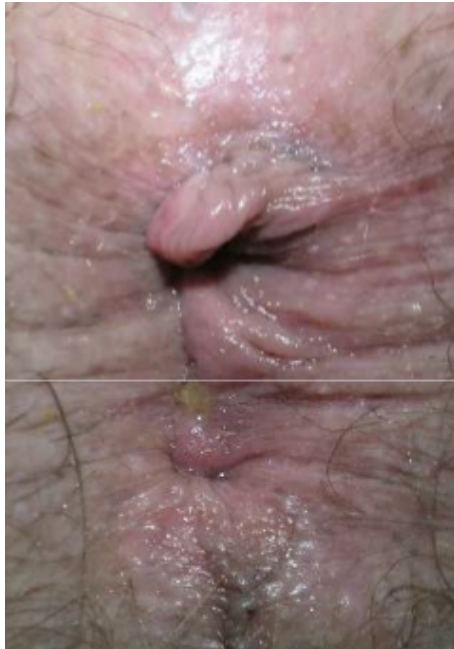Grade II : passing beyond linea dentata with spontaneous reduction






Internal Hemorrhoids: Prolapse

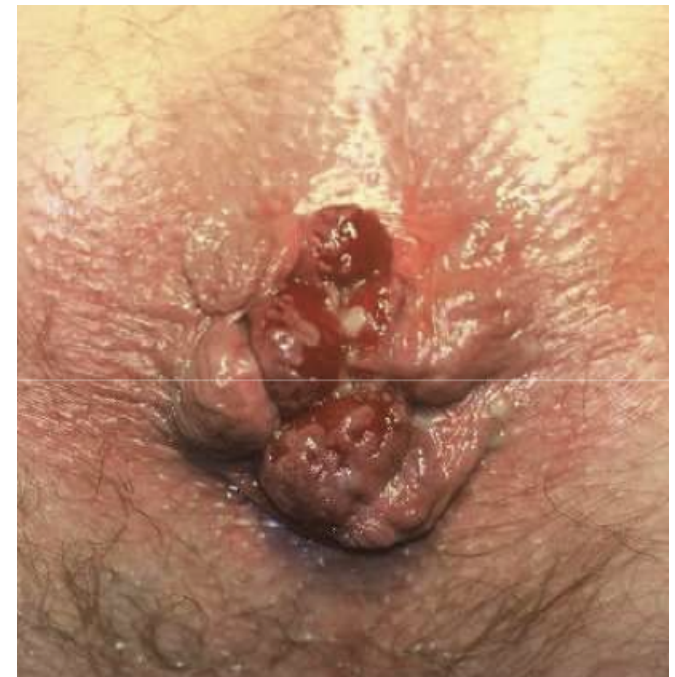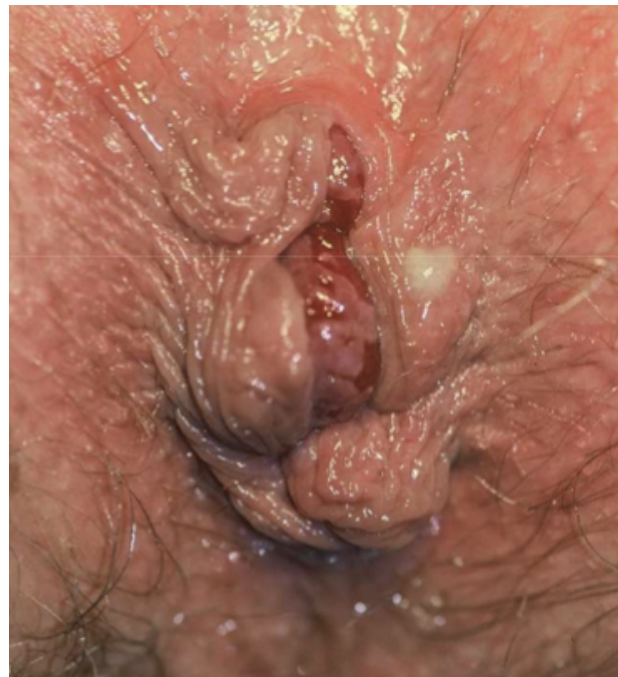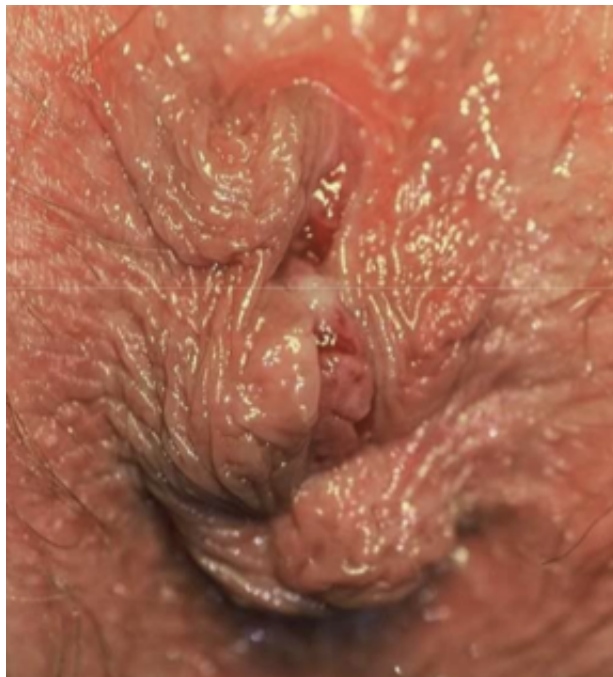Grade III : Manual reduction of hemorrhoids






Internal Hemorrhoids: Prolapse

Grade IV : reduction of hemorrhoids not possible





Internal Hemorrhoids: Prolapse

Treatment


A. Instrumental/surgical treatment needed?

Grade I-II-III: IR coagulation - Rubber band ligation

Grade III-IV: Surgery

B. Stool softeners ¹

¹ Jensen Act Chir Scand1988

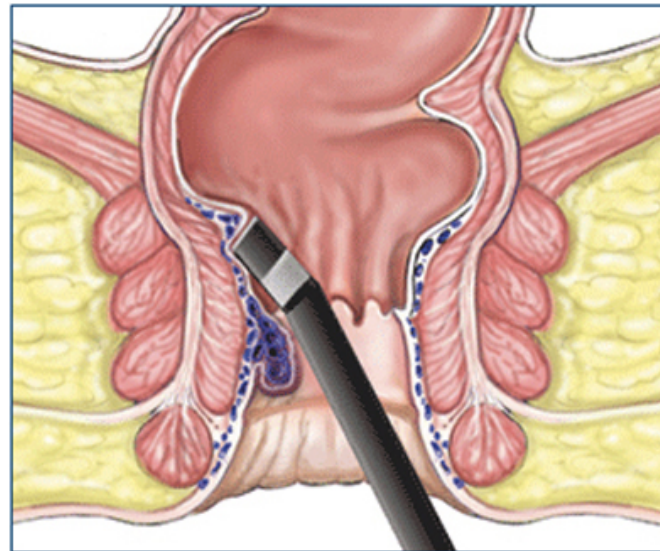



Internal Hemorrhoids: Prolapse

Instrumental Treatment

AIM:

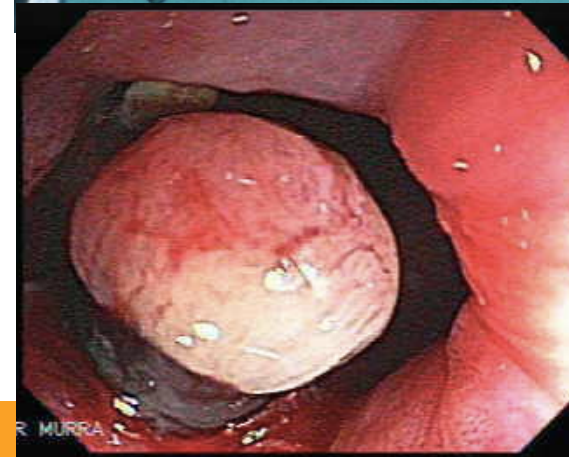
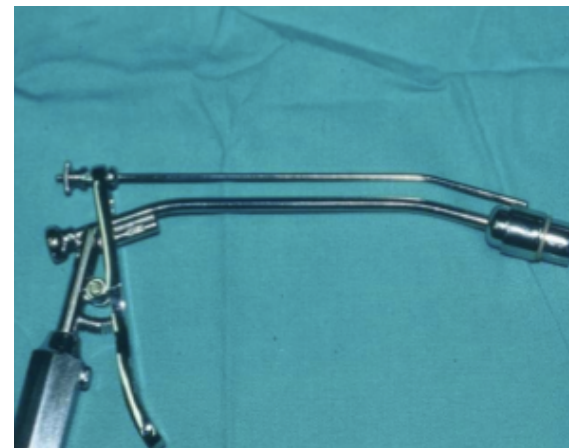
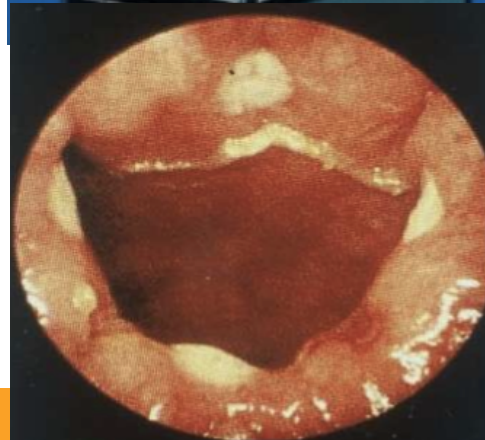- NOT: a resection of hemorrhoids
- LIFTING of hemorrhoids = 'restoring' original position






Internal Hemorrhoids: Prolapse

Instrumental Treatment






Internal Hemorrhoids: Bleeding

Symptoms

- blood around stools
- blood dripping in the water closet
- blood on paper
- painless




Internal Hemorrhoids: Bleeding

Treatment

- Transit 'normalization'

Cochrane Collaboration 2005

- Instrumental or Surgical therapy
 - Treatment needed?
 - Grade I-II-III: Instrumental
 - Grade IV or relapsing: Surgical




Internal Hemorrhoids: Bleeding

Infra-Red coagulation – Rubber Band Ligation

Table 4 Follow-up after treatment of haemorrhoids with rubber band ligation (RBL) and infra-red coagulation (IRC). Data are presented as absolute numbers and percentages (%)

	Symptom-free	Mild symptoms	Full recurrence of symptoms	Total
RBL				
First-degree	21 (58)	8 (22)	7 (19)	36
Second-degree	2 (22)	5 (55)	2 (22)	9
Third-degree	5 (100)	0 (0)	0 (0)	5
Total	28 (56)	13 (26)	9 (18)*	50
IRC				
First-degree	18 (50)	10 (28)	8 (22)	36
Second-degree	8 (50)	6 (38)	2 (13)	16
Third-degree	1 (33)	1 (33)	1 (33)	3
Total	27 (49)	17 (31)	11 (20)†	55




Internal Hemorrhoids: Bleeding

Infra-Red coagulation – Rubber Band Ligation

Table 3 Side-effects of treatment of haemorrhoids with rubber band ligation (RBL) and infra-red coagulation (IRC)

	RBL (n = 59)	IRC (n = 63)
None	9	11
Mild bleeding	22	31
Severe bleeding	–	–
Pain/discomfort		
VAS > 5	36	17
Mean VAS (0–10)	5.5 (3.7)	3.3 (3.3)
At follow-up contact	9	3
Fever	2	–
Urine retention	1	2
Soiling	1	1
Proctitis	–	1

One patient in the IRC group developed a painful anal fissure.
VAS, visual analogue scale.



Internal Hemorrhoids:

Instrumental therapy: complications

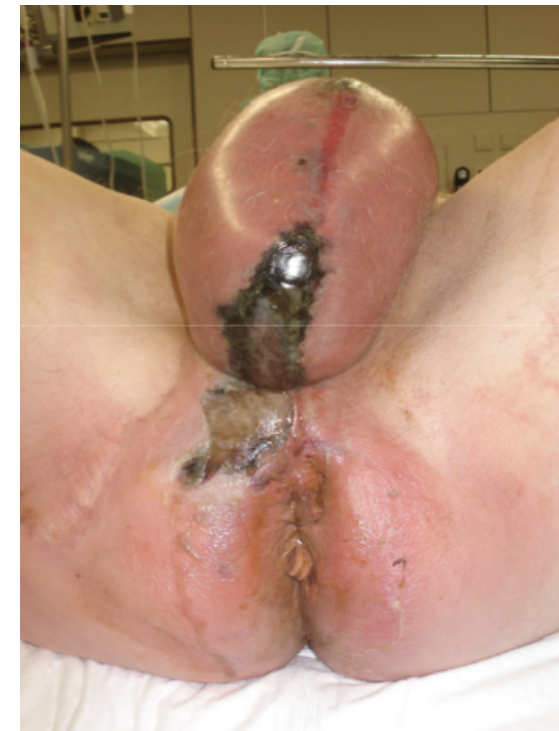- Pain
- Urinary retention / Dysuria
- Bleeding

no rubber band ligation if INR therapeutic

- Septicemia

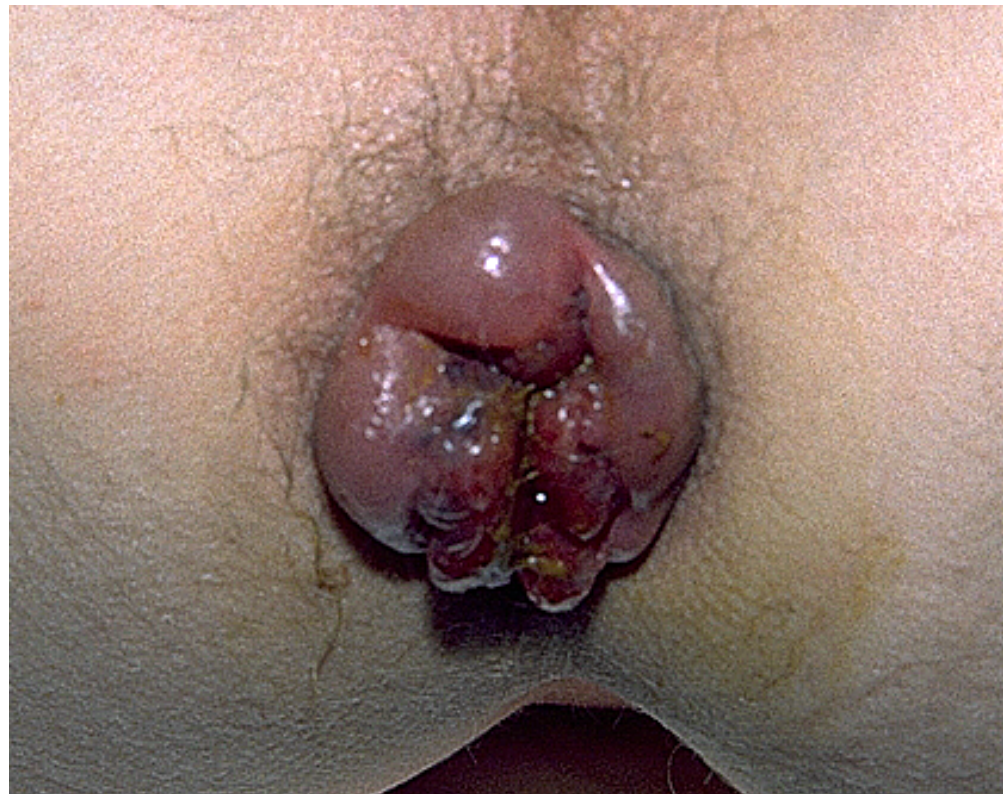fever / abscedation / fistulization

Fournier gangrene – fatal outcome



Internal Hemorrhoids: Thrombosis

Clinical picture



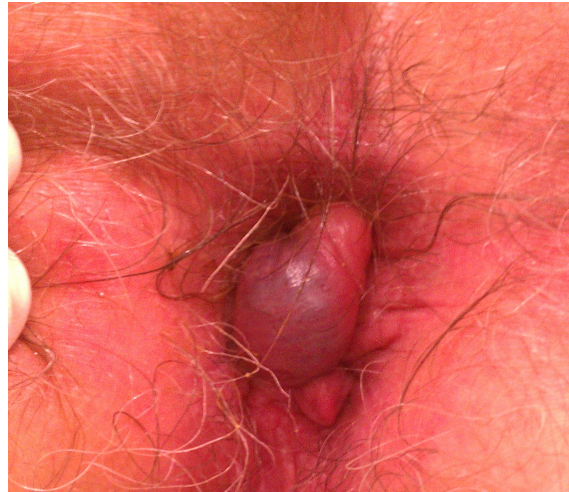Internal Hemorrhoids: Thrombosis

Treatment

- Medical
 - NSAID / corticoids
 - local corticosteroid
 - analgetics
- Surgical
 - Hemorrhoidectomy

External Hemorrhoids: Thrombosis

Clinical picture



External Hemorrhoids: Thrombosis

Treatment

- Medical
 - NSAID / corticosteroids
 - local corticosteroid
 - analgetics
- Instrumental (hard – no clear edema – localized)
 - Incisional
 - Excisional

Indications for surgery

- Anemia due to hemorrhoidal blood loss
- Frequently recurring internal/external hemorrhoidal thrombosis
- Internal prolapse grade 4 and symptomatic